Decoding early human TB lesions with multimodal bio-computing identifies a permissive alveolar niche for infection

UCLA

Robert L. Modlin
David Geffen School of Medicine at UCLA

INTRODUCTION

The earliest stages of tuberculosis (TB) pathogenesis remain poorly characterized, in part due to the difficulty of resolving heterogeneous human lung lesions. To address this, we developed a multimodal bio-computing framework that integrates spatial transcriptomics, single-cell RNA sequencing, and high-resolution tissue imaging from human lung biopsies.

METHODS

Using advanced computational pipelines for cell state alignment, spatial mapping, and transcript–pathogen co-localization, we decoded the organization of early pulmonary lesions.

RESULTS

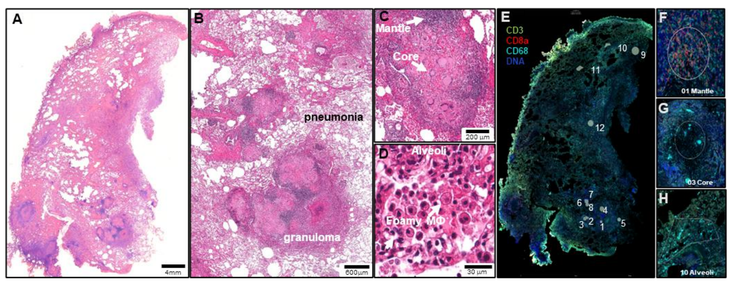

Figure 1. GeoMx spatial profiling of the human transcriptome in pulmonary TB (PTB). (A-B) Pulmonary TB biopsy specimen from PTB 21.1a, H&E. (C) Organized granuloma, H&E, (D) Pneumonitis showing alveoli with foamy macrophages, (E) Regions of interest (ROI), serial section, immunofluorescence, (F) Mantle- ROI 01, (G) Core- ROI 03, (H) Alveoli- ROI 10

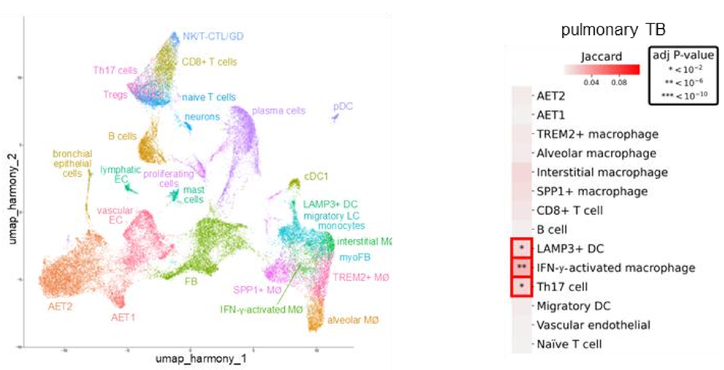

Figure 2. UMAP of PTB scRNAseq data and Jaccard overlap of the GeoMx spatial profiling data with the PTB scRNA-seq data.

RESULTS

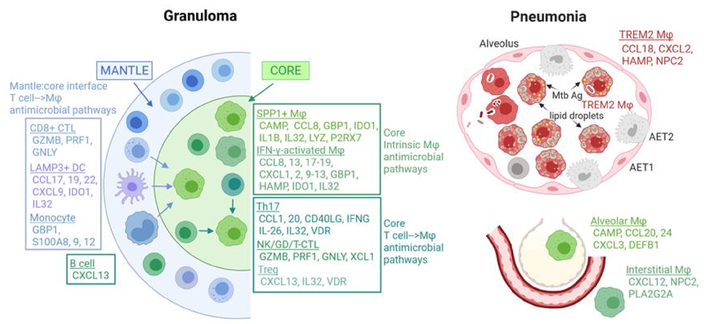

Figure 2. Distribution of antimicrobial genes in PTB identified by integrating the GeoMx spatial profiling data with the scRNA-seq data. Antimicrobial gene expression is high in the granuloma mantle and core, but low in the alveoli, espcially in TREM2 macrophages.

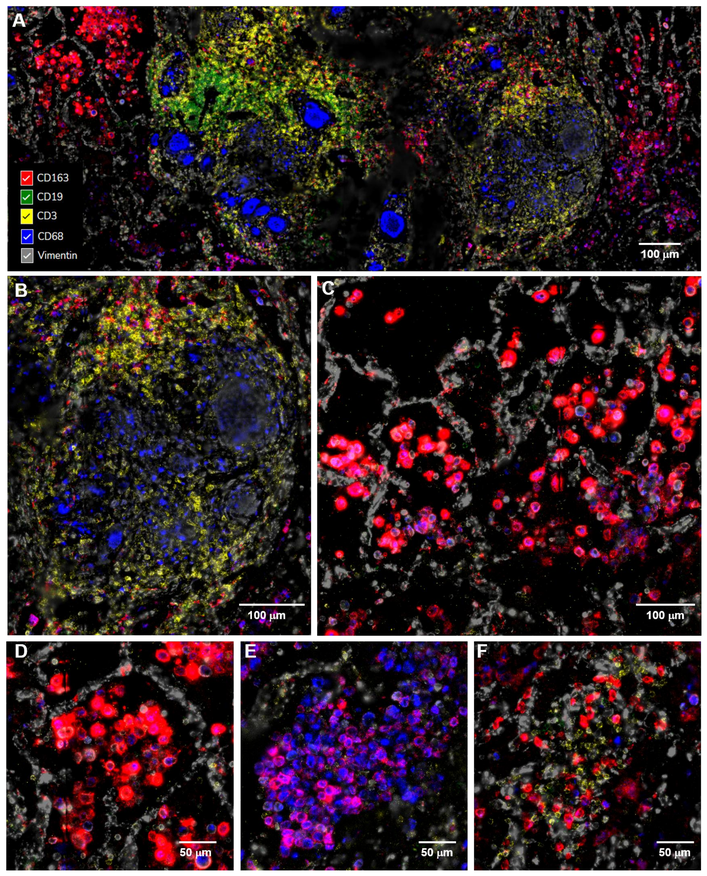

Figure 4. Immunofluorescence images obtained using the CosMx spatial profiling with the human protein panel, illustrating the spatial expression of immune cell markers in active pulmonary tuberculosis (TB). (A) Overview of immune cell distribution within the active pulmonary TB lesion. The granuloma core contains CD68+ macrophages (blue) and CD3 + T cells (yellow). The granuloma mantle contains CD3 + T cells (yellow) and CD19 + B cells (green). The alveoli contain prominent CD163 + macrophages (red), some with CD68 expression (blue). Vimentin (gray) is present on many cells in the lesions but particularly highlights the alveolar structure by staining alveolar epithelial cells. (B) Localization of immune cells within granulomas. (C–F) Distribution of immune cells in alveolar regions showing heterogeneity of macrophage phenotype and variability in the presence or absence of T cells. Scale bars: 100 µm (low magnification) and 50 µm (high magnification).

RESULTS

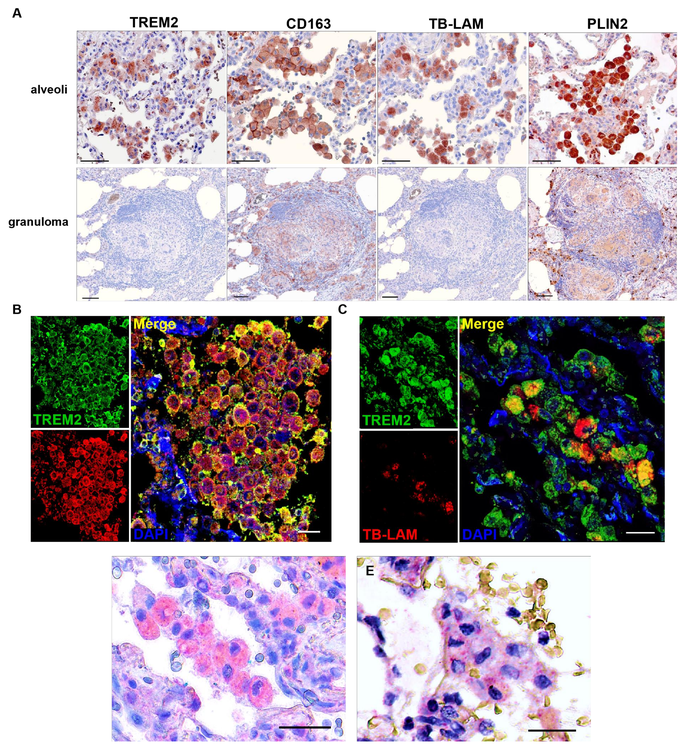

Figure 5: Immunohistochemical analysis of the alveolar pneumonia in pulmonary tuberculosis (PTB) tissue shows that (A) TREM2-associated macrophage signature markers, TREM2, CD163 and PLIN2, as well as *Mtb* lipoarabinomannan (LAM) are enriched in areas of alveolar pneumonia compared to the granulomas, (B) TREM2 is co-expressed with CD163, (C) *Mtb* LAM colocalizes with TREM2⁺ macrophages, (D) *Mtb* proteins (red staining) accumulate within foamy macrophages within alveoli, counterstain hematoxylin, and (E) *Mtb* RNA is observed as red puncta present in foamy macrophages within alveoli by in situ hybridization (RNAscope), counterstained with hematoxylin. The brown staining cells represent erythrocytes. From four independent PTB specimens (scale bars: 40 µm for A; 20 µm for B–E).

CONCLUSIONS

- We show that alveolar TB pneumonia are dominated by TREM2⁺ lipid-laden macrophages with sparse T cells, minimal antimicrobial gene expression, and abundant *Mycobacterium tuberculosis* antigens and transcripts. In contrast, granuloma cores exhibit robust antimicrobial programs and organized immune architecture.
- Mechanistic studies reveal that the mycobacterial virulence lipids PDIM and free mycolic acids potently induce TREM2 expression, drive lipid-droplet accumulation, and suppress autophagy in human macrophages, thereby establishing a permissive niche that enhances intracellular *M.tb* viability.
- We show this state is pharmacologically reversible using: 1,25-dihydroxyvitamin D_3 which downregulates TREM2, restores autophagy, reduces lipid droplets, and decreases bacterial survival.
- Together, these findings molecularly define the earliest permissive alveolar niche for *M.tb*, provide a mechanistic basis for asymptomatic transmission, and identify tractable immunometabolic pathways for early host-directed intervention.

Created with BioRender Poster Builder